

*Department of
Radiology
Techniques
The Second Stage*



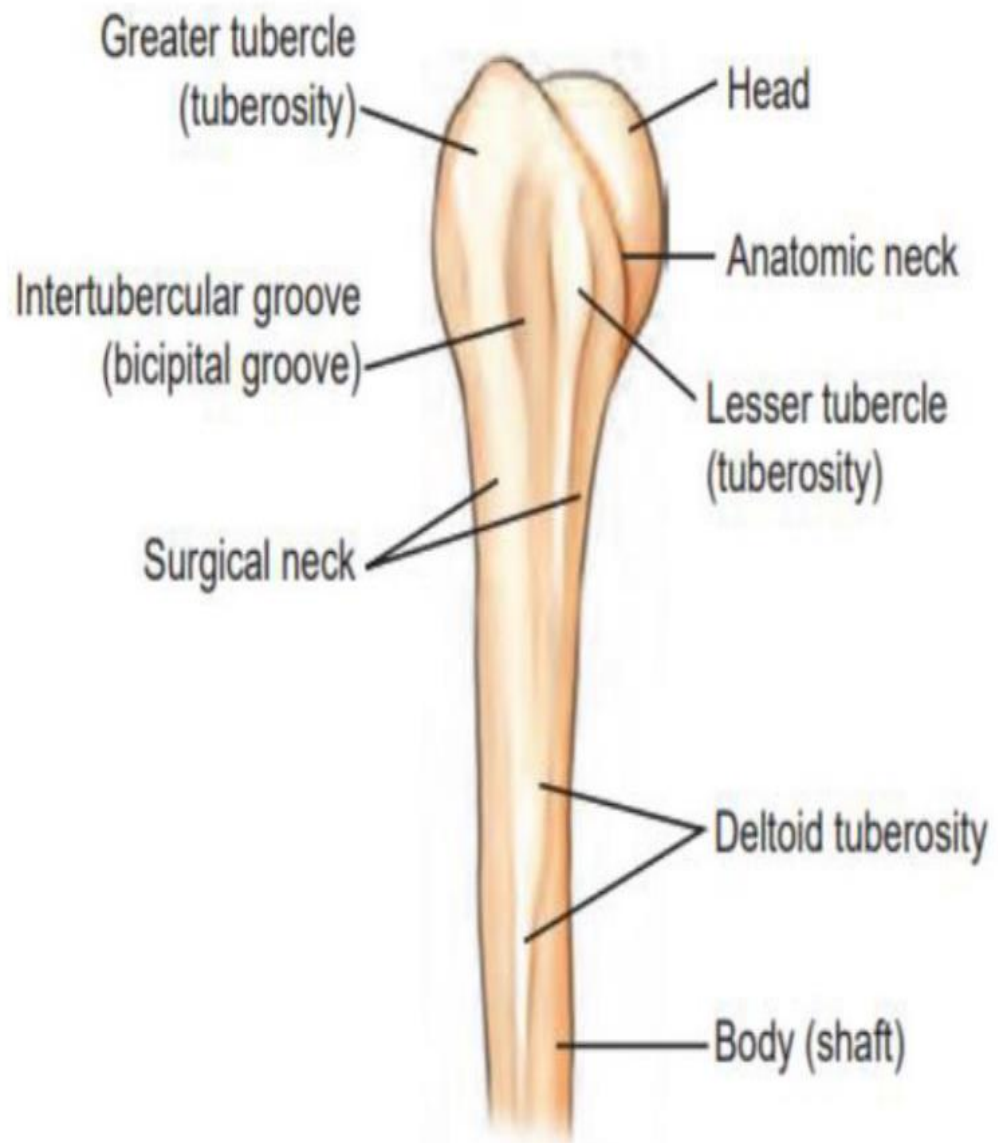
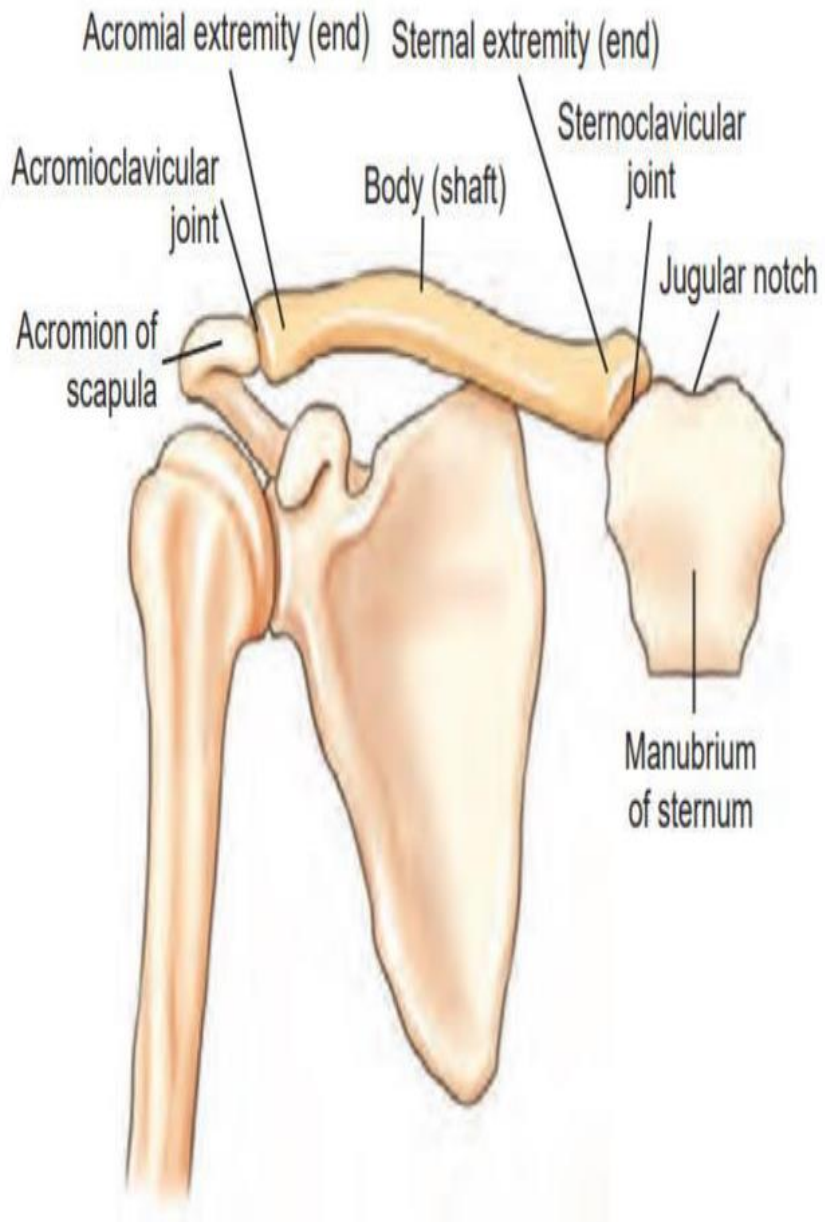
Shoulder Joint

Lecture 6

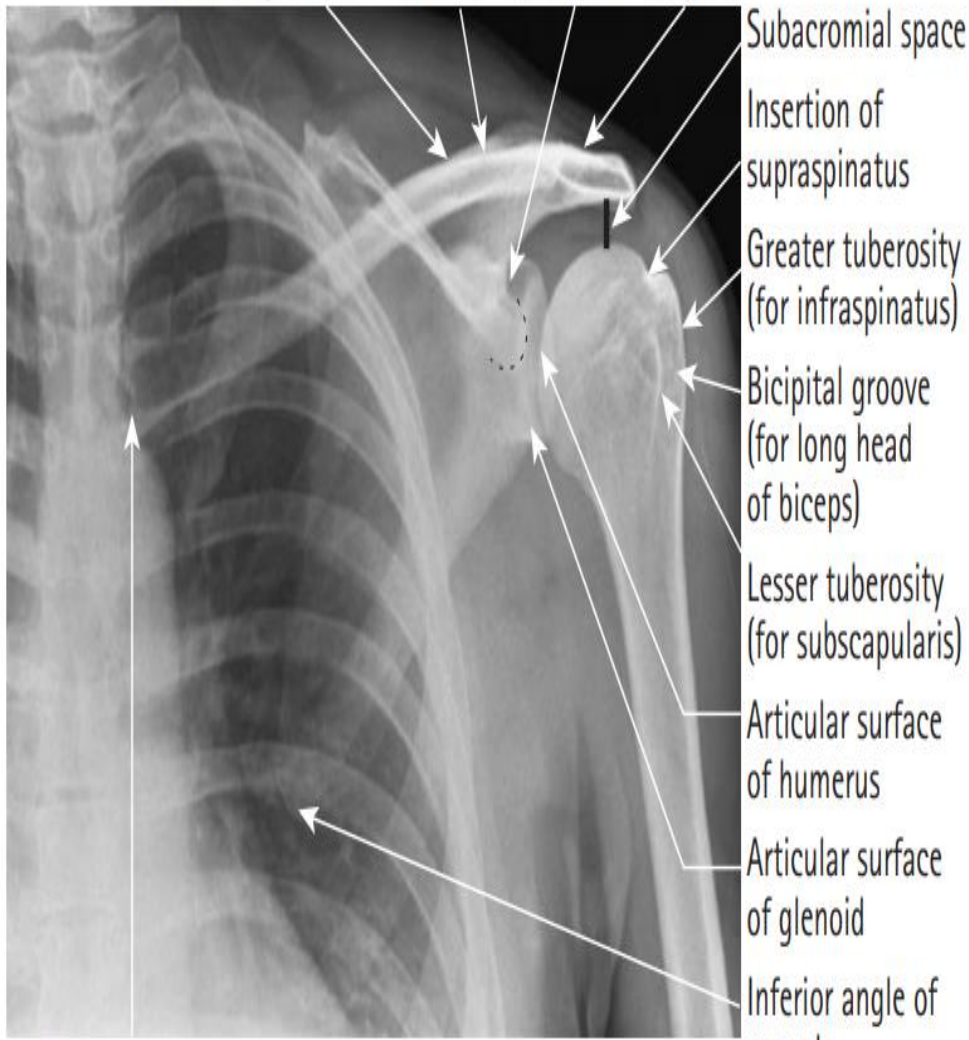
Assist. Lecturer

Tariq Nadhim Jassim

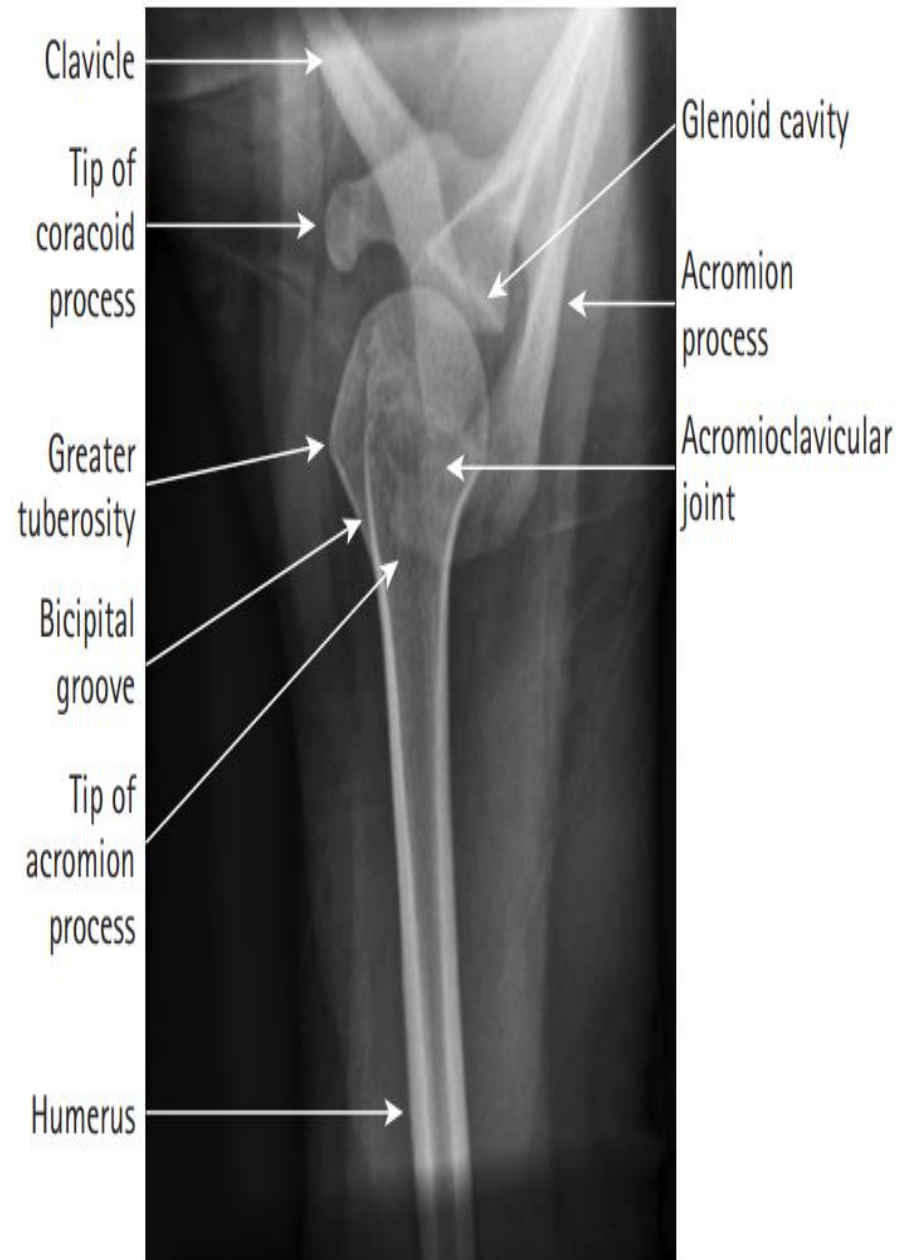
Fadhil Aad Leftah Al-zurfi



Superior border of spine of scapula/
acromion process Superior border of clavicle Tip of coracoid process Acromion process of scapula



Sternoclavicular joint



Projections of Shoulder Joint

1- Antero-Posterior (15 degrees)

2- Superior-Inferior (axial)

3- Inferior-Superior

4- Lateral

5- Oblique 'Y' projection

1- Antero-Posterior (15 degrees)

Position of Patient

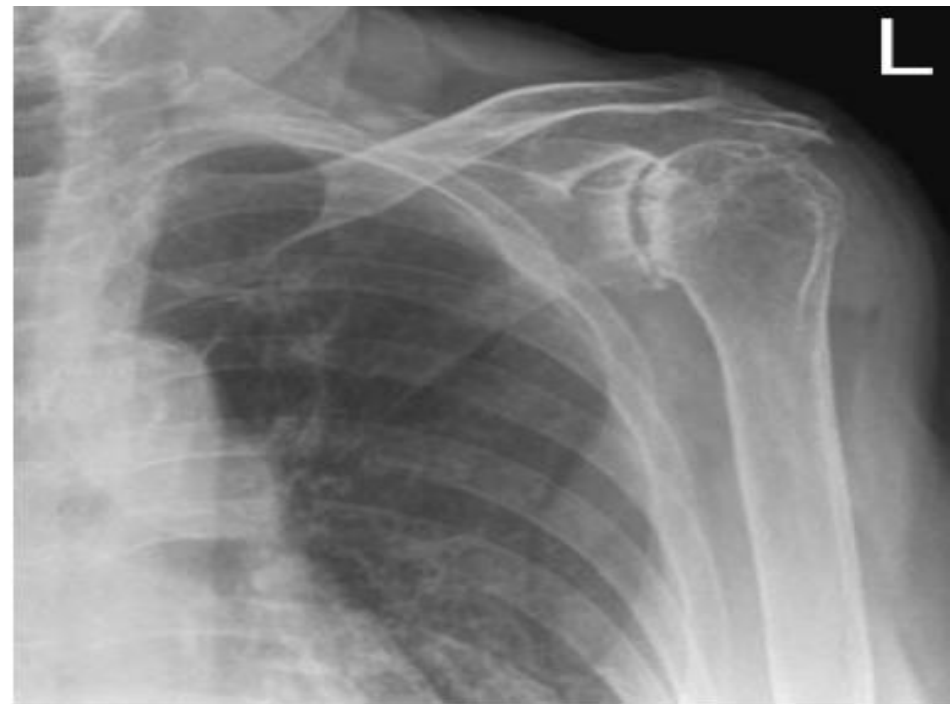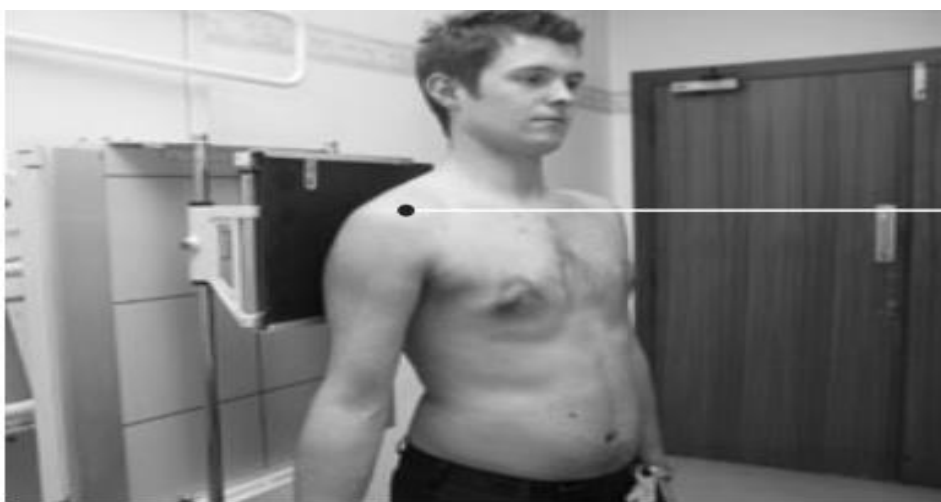
- The patient stands with the affected shoulder against the cassette and is rotated 15 degrees to bring the shoulder closer to the cassette and the plane of the acromio-clavicular joint parallel to the central beam.
- The arm is supinated and slightly abducted away from the body. The medial and lateral epicondyles of the distal humerus should be parallel to the cassette.
- The cassette is positioned so that its upper border is at least 5 cm above the shoulder to ensure that the oblique rays do not project the shoulder off the cassette.

Direction and centring of the X-ray beam

- The horizontal central ray is directed to coracoid process of the scapula. The beam can then be directed caudally and collimated.

Essential image characteristics

- The image should demonstrate the head and proximal end of the humerus, the inferior angle of the scapula and the whole of the clavicle.
- The head of the humerus should be seen slightly overlapping the glenoid cavity but separate from the acromion process.
- Arrested respiration aids good rib detail in acute trauma.



Antero-posterior radiograph of shoulder showing severe arthritic disease

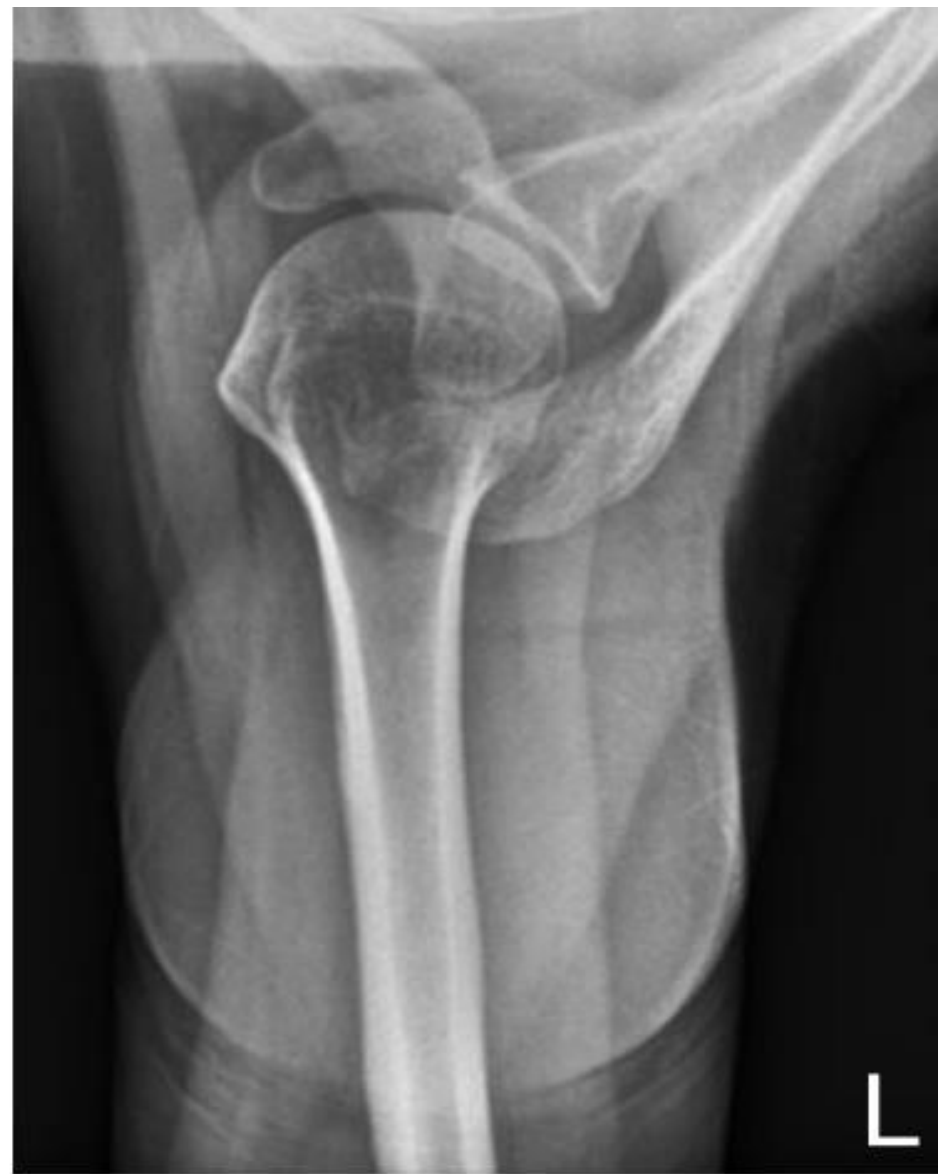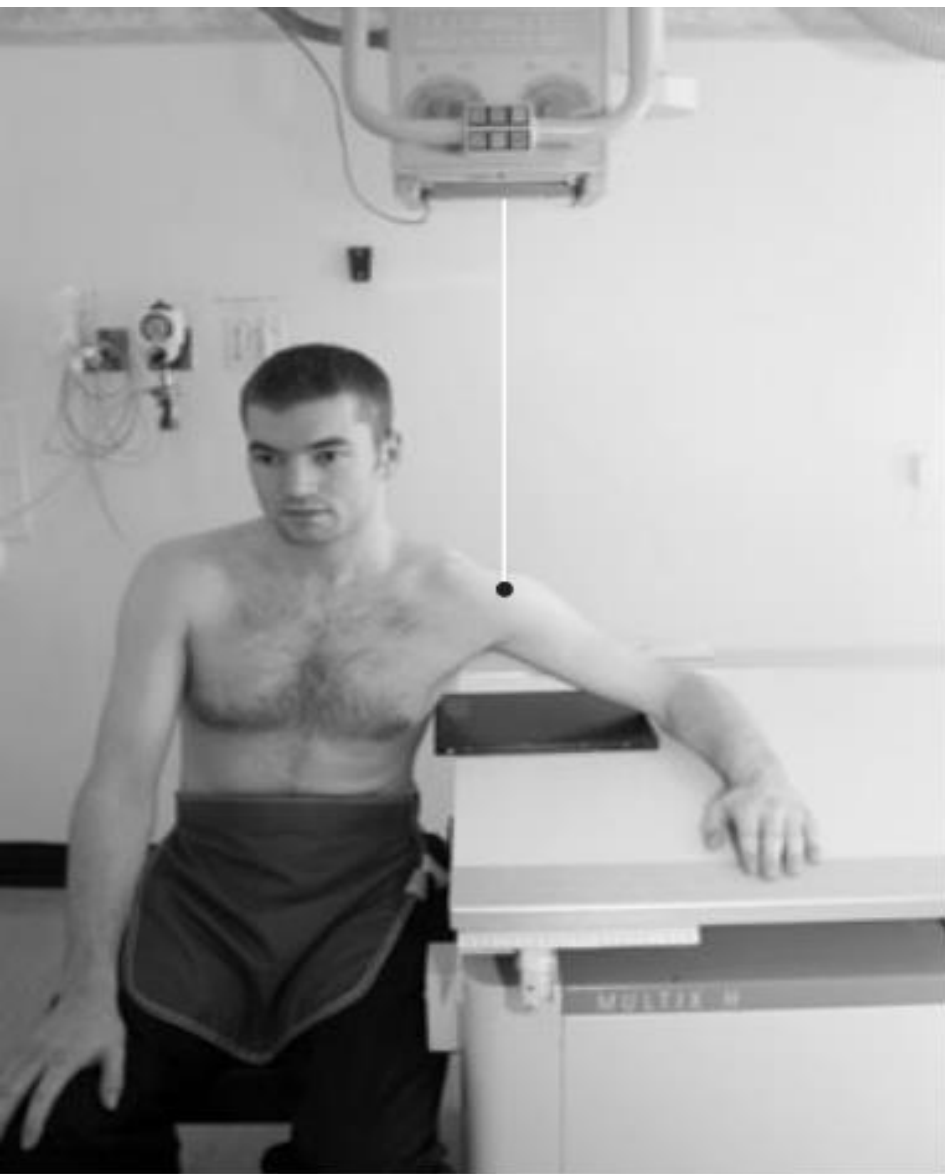2- Superior-Inferior (axial)

Position of Patient

- The patient is seated at the side of the table, which is lowered to waist level.
- The cassette is out bucky (8x10) placed on the tabletop, and the arm under examination is abducted over the cassette.
- The elbow can remain flexed, but the arm should be abducted to a minimum of 45 degrees .

Direction and centering of the X-ray beam

- The vertical central ray is directed through the proximal aspect head of humeral head.



Normal supero-inferior image of the shoulder

3- Inferior-Superior (axial)

This projection may be used as an alternative to the superior-inferior projection in cases of dislocation or when the patient is supine, since it can be taken even when the patient is able to abduct the arm only slightly. An (12x10) cassette.

Position of Patient

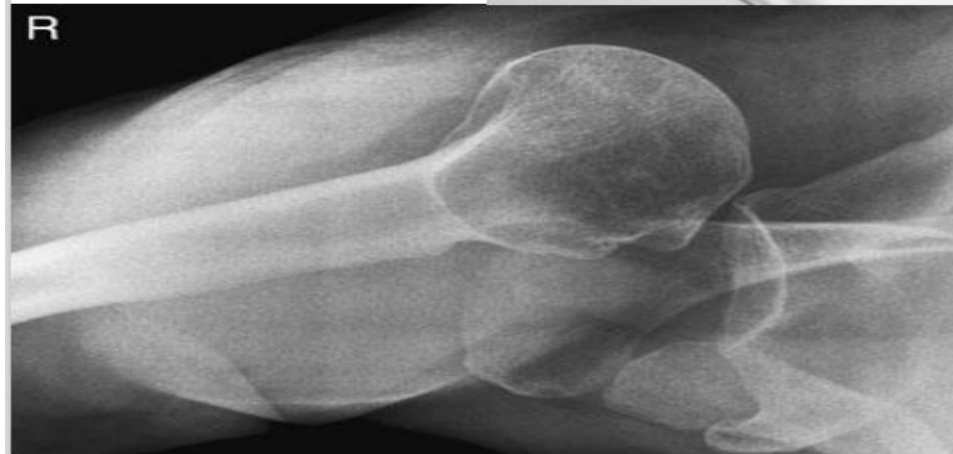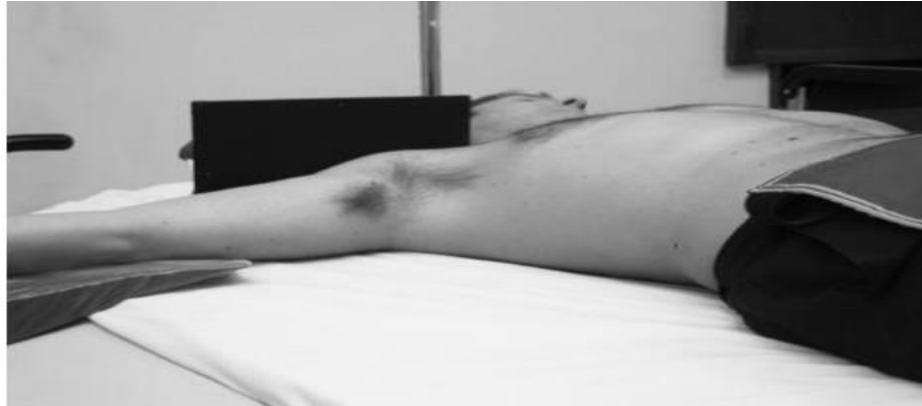- The patient lies supine, with the arm of the affected side slightly abducted and supinated without causing discomfort to the patient.
- The affected shoulder and arm are raised on non-opaque pads.
- A cassette is supported vertically against the shoulder and is pressed against the neck to include as much as possible of the scapula on the film .

Direction and centering of the X-ray beam

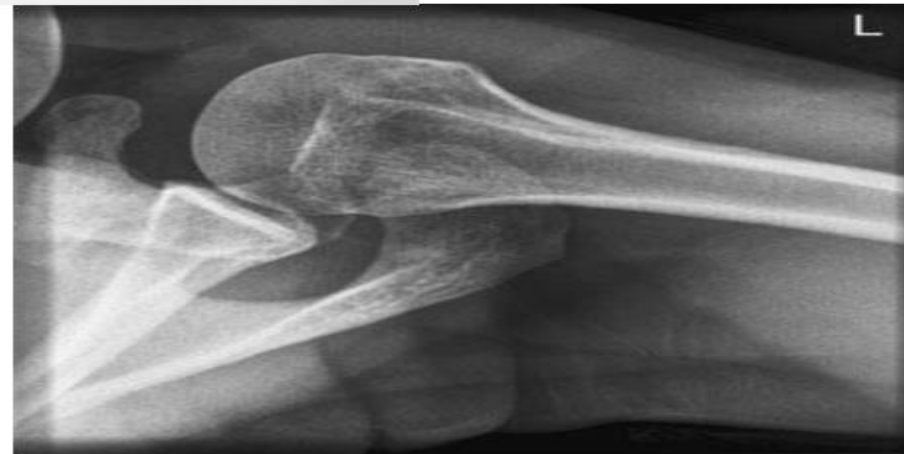- The horizontal central ray is directed towards the axilla.

Image Characteristics

- The image should demonstrate the head of the humerus, the acromion process, the coracoid process and the glenoid cavity of the scapula.
- The lesser tuberosity will be in profile, and the acromion process and the superior aspect of the glenoid will be seen superimposed on the head of humerus.



Axial radiograph of the shoulder showing posterior dislocation



Normal infero-superior radiograph of the shoulder

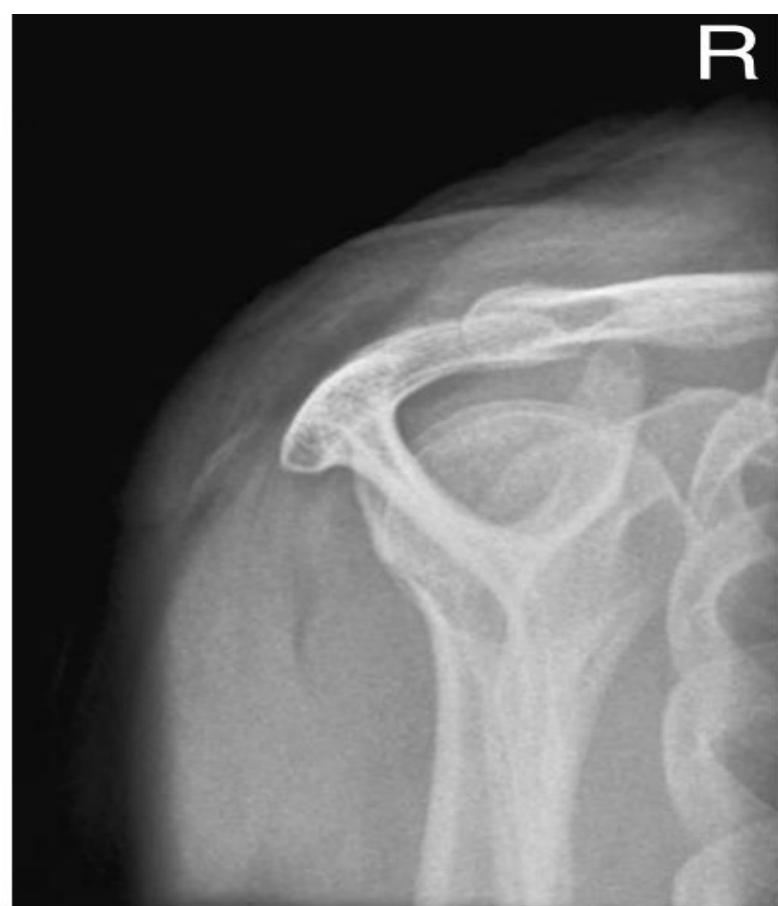4- Lateral

Position of Patient

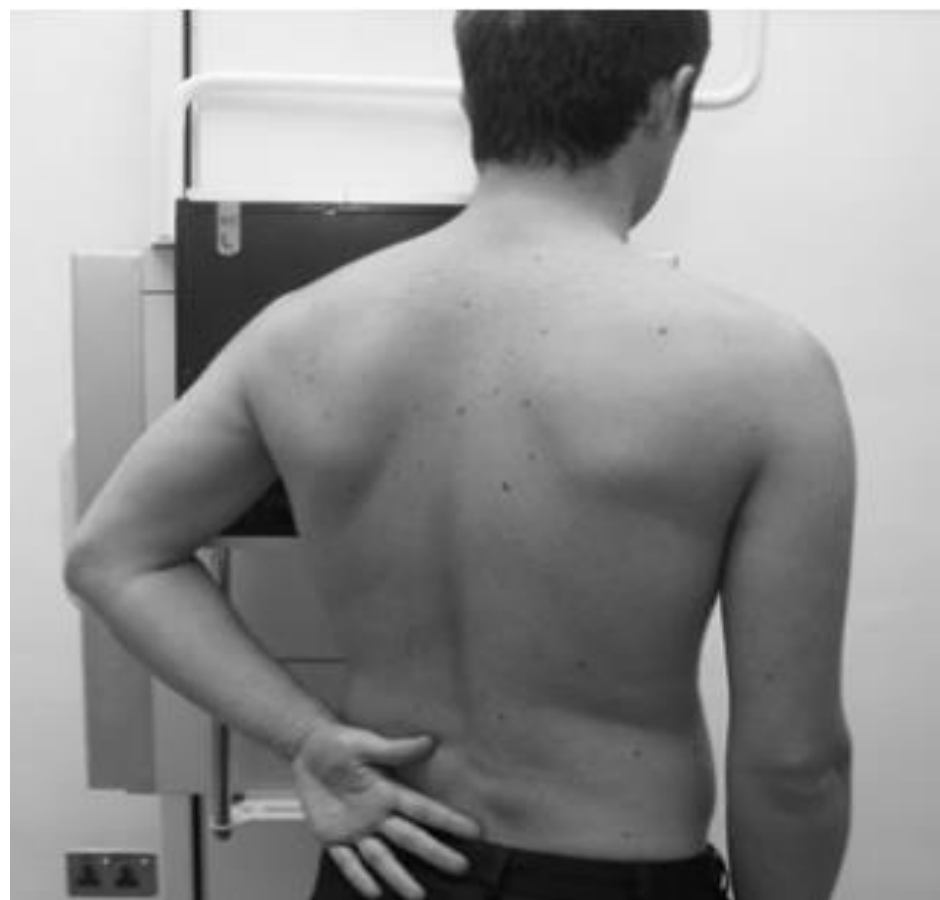
- The patient stands or sits facing the cassette, with the lateral aspect of the affected arm in contact.
- The affected arm is extended backwards, with the dorsum of the hand resting on the patient's waist.
- The patient is adjusted so that the head of the humerus (coracoid process) is in the centre of the cassette.
- The patient is now rotated forward until a line joining the medial and lateral borders of the affected scapula is at right-angles to the cassette. The body of the scapula is now at right-angles to the cassette, and the scapula and the proximal end of the humerus are clear of the rib cage.

Direction and centering of the X-ray beam

- The horizontal central ray is angled 10 degrees caudally and centered to the head of the humerus.



Normal radiograph of lateral shoulder outlet



5- Oblique 'Y' projection

Position of Patient

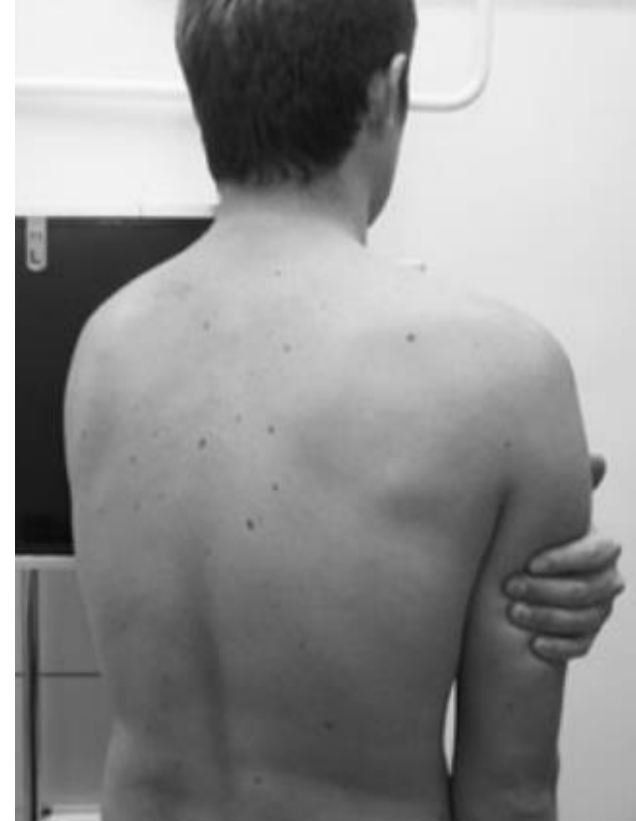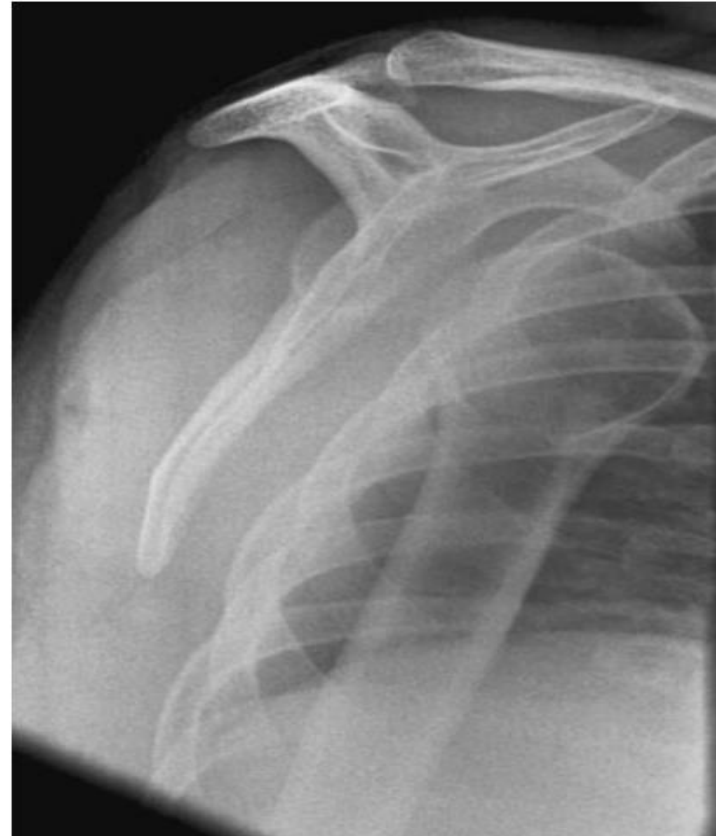- The patient stands or sits with the lateral aspect of the injured arm against an erect cassette and is adjusted so that the axilla is in the centre of the film.
- The unaffected shoulder is raised to make the angle between the trunk and cassette approximately 60 degrees. A line joining the medial and lateral borders of the scapula is now at right-angles to the cassette.
- The cassette is positioned to include the superior border of the scapula.

Direction and centring of the X-ray beam

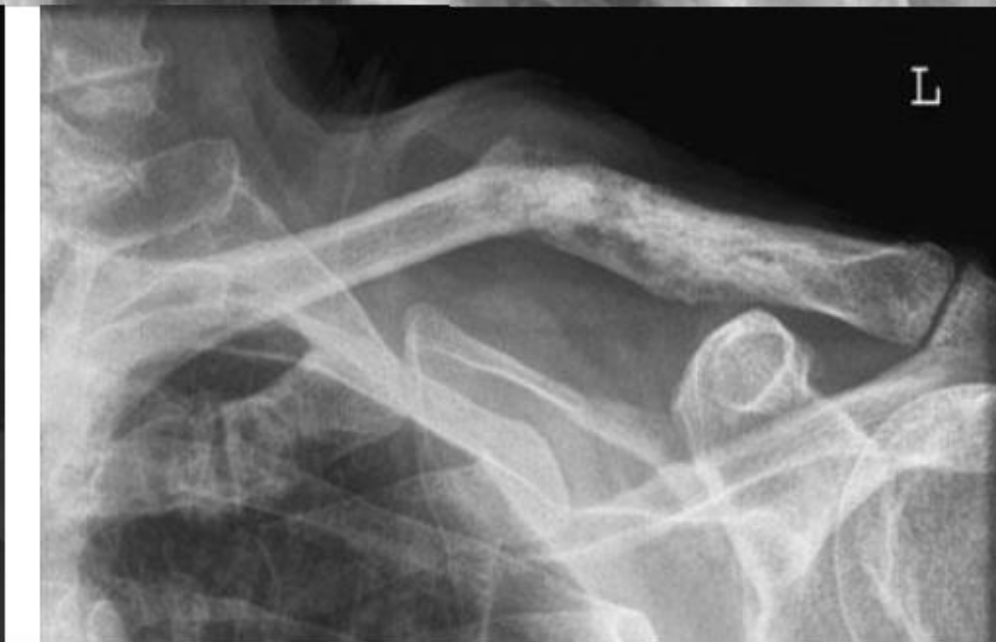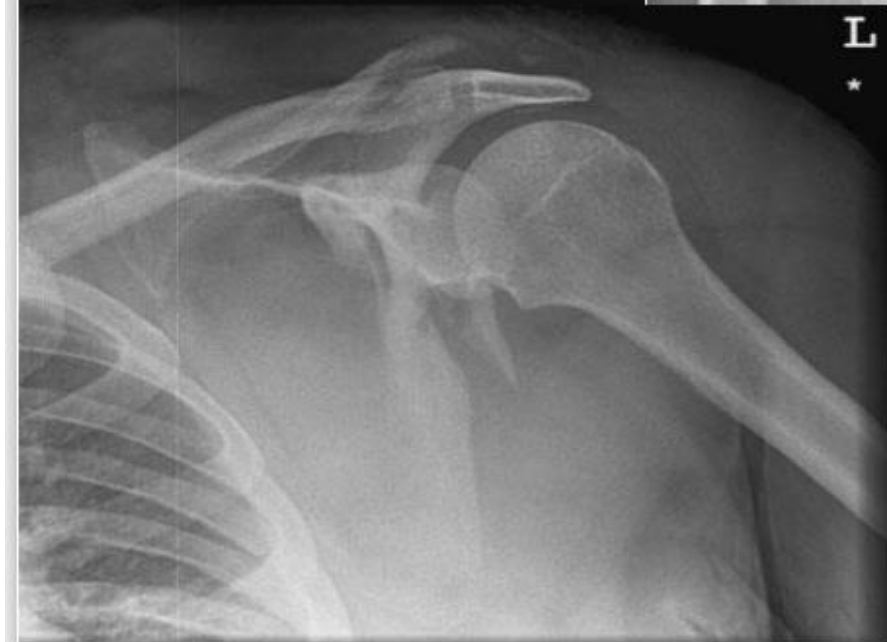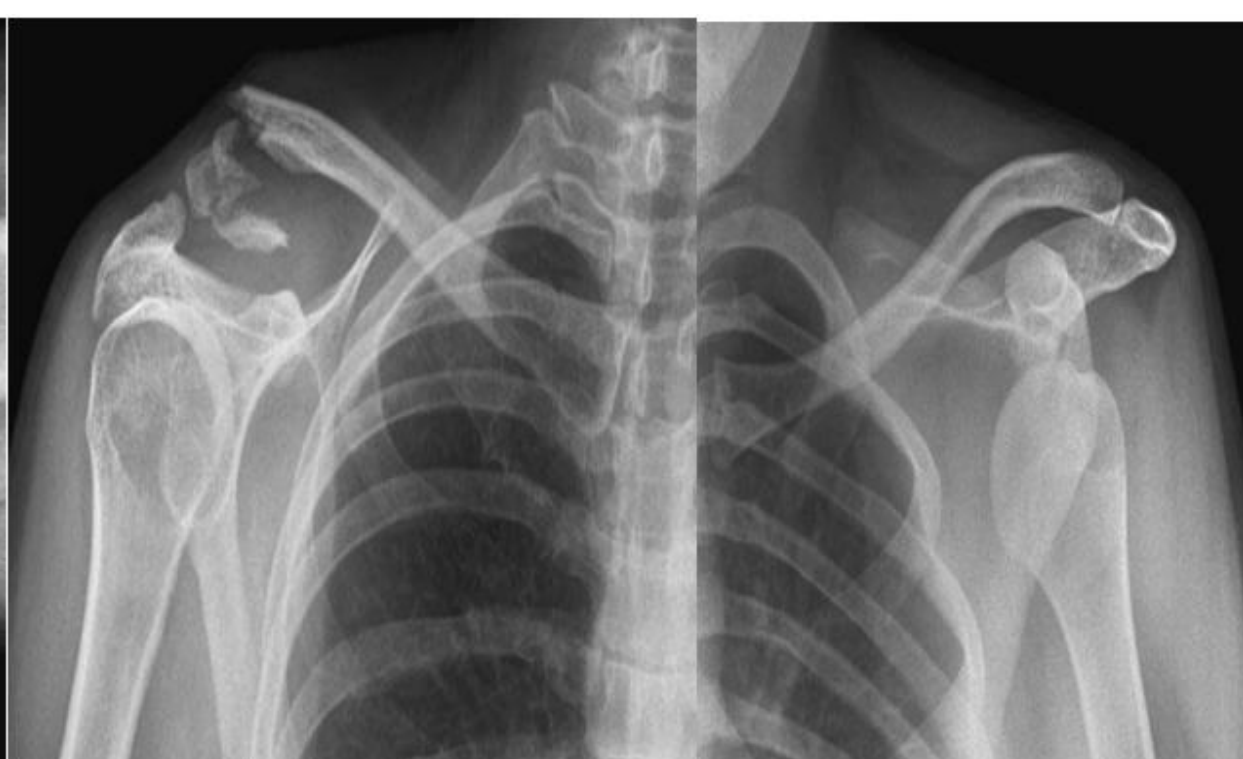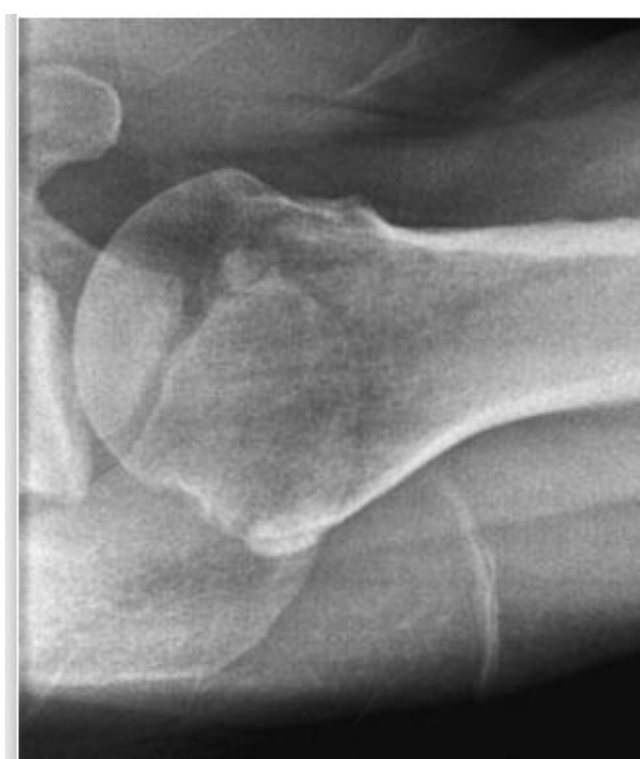- The horizontal central ray is directed towards the medial border of the scapula and centered to the head of the humerus

Essential image characteristics

- The body of the scapula should be at right-angles to the cassette, and the scapula and the proximal end of the humerus are clear of the rib cage.
- The exposure should demonstrate the position of the head of the humerus in relation to the glenoid cavity between the coracoid and acromion processes.



Lateral oblique radiograph of the shoulder showing anterior dislocation



Thanks

The word "Thanks" is written in a large, pink, cursive font with a sparkling, glitter-like texture. The text is centered and surrounded by decorative pink roses and green leaves on thin black stems. One rose is positioned above the 'h', another to the left of the 'T', and a larger one to the right of the 's'.